

## Case report: Mammary Gland Tubulocarcinoma on Dog Miniature Dachshund at Animal Hospital University of Brawijaya Indonesia

Ahmad Fauzi<sup>1\*</sup>, Albiruni Haryo<sup>1</sup>, Isma Prasthani Hutami Putri<sup>2</sup>, Fajar Shodiq Permata<sup>1</sup>, Nurina Titisari<sup>1</sup>, Anggit Prio Pambudi<sup>2</sup>

<sup>1</sup>Faculty of Veterinary Medicine, University of Brawijaya, Malang, Jawa Timur 65151 Indonesia

<sup>2</sup>Teaching Animal Hospital University of Brawijaya, Malang, Jawa Timur 65151 Indonesia

\*Corresponding Author: drhfauzi@ub.ac.id

**KeywordS:** cytology, histopathology, mammary tumors, tubulocarcinoma.

### INTRODUCTION

In 1 study of 2000 dogs In America, 23% were found to have died due to cancer [1]. Mammary tumors are one of the most common neoplasms of female dogs [2]. This tumor mainly affects middle-aged dogs (9 to 11 years), with an increased incidence that begins at about 6 years old [3]. Sex steroid hormones are thought to have a major role during the early stages of carcinogenesis due to the presence of estrogen and progesterone receptors in higher proportions in most mammary tumours. [3,4]. In addition to hormonal influences, the use of products containing medroxyprogesterone acetate (progestin and estrogen combinations) to prevent estrus in dogs is also associated with an increased incidence of mammary tumors [5]. Mammary tumors can interfere with the physiological appearance and physiological function of the body. This report aims to describe cases of mammary tumors in dogs supported by hematology laboratory examination, blood biochemistry, cytology and histopathology.

### CASE REPORT

An 8y old female Dachshund Miniature Dog named Casey came to Teaching Animal Hospital University of Brawijaya, May 2018, with a large ventrocaudal adominal mammary mass. She was anorexic, and depressed, no vaccination history, never mated, last wormed April 2018. Results of the physical examination were, weight 11.5 kg, temperature 39,7 C, HR 120/minute, RR 48/minute, CRT <2 sec. There were visible lumps on the left mammary glands of the three nipples from caudal and petechia around the abdomen (Fig. 1). Palpation of affected mammary glands found several hard nodules within the glands. These areas were further investigated by performing FNA's, and cytology. Also CBC, and blood chemistry were performed.

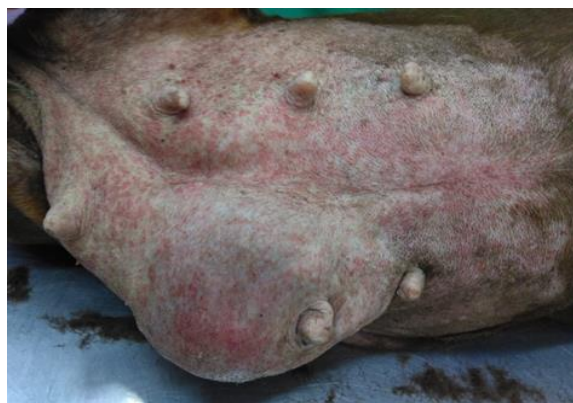

Figure 1. Gross findings during the physical examination. The patient exhibited had mammary mass in the left caudal mammary gland (13.5 cm × 7.6 cm in size).

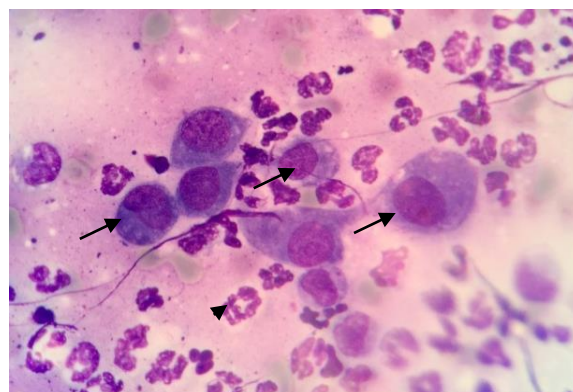


Figure 2. Fine needle aspiration (FNA) of the mammary gland tumors, the cells have multiple nucleoli, anisocytosis, anisokaryosis (arrow) and neutrophil (arrowhead) (Diff-Quik, × 1000).

Differential Diagnosis: Mastitis, Mammary Tumor, hernia inguinal. Tentative Diagnosis : Mammary gland tubulocarsinoma. Prognosis : Guarded.

The treatment elected in this case was to perform regional mastectomy of affected mammary glands. Postoperative treatment was Amoxicillin clavulanic acid, Karprofen, Fufang®, Sangobion® capsule and Vitamin Seloxy® tab.

## RESULT AND DISCUSSION

The results of hematologic and blood biochemical examinations on the first day (Table 1) showed leukocytosis, granulocytosis and hyperglobulinemia which indicated a systematic pathological response associated with inflammation or infection, likely due to mammary tumor. Leukocytosis accompanied by increased globulin may be associated with chronic inflammation and / or the presence of neoplasia in dogs [6]. In addition, the results of blood tests was the presence of real thrombocytopenia. Thrombocytopenia is a clinical finding that often accompanies the incidence of neoplasia [7]. In this case, we consider the pathogenesis of thrombocytopenia was due to excessive platelet destruction as the primary manifestation of infection or inflammation. Excessive platelet usage may occur in cases of acute infections such as infectious agents (bacteria, viruses, parasites) or inflammation which led to excessive endothelial vascular damage and caused vasculitis [8].

Table 1. Complete blood count and blood chemistry results on the 1st and 14th days

Test	Unit	Standart	Results	
			1st Day	14th Days
WBC	10 <sup>3</sup> /L	6-17	25,2	9,6
Lym	10 <sup>3</sup> /μL	1-4.8	2,7	2,2
Mon	10 <sup>3</sup> /μL	0.2-1.5	2	0,7
Gra	10 <sup>3</sup> /μL	3-14	20,6	6,7
LY	%	12-30	11,5	22,9
Mon	%	2-4	8,8	7,2
Gra	%	62-87	79,7	69,9
RBC	10 <sup>6</sup> /μL	5.5-8.5	4.94	5.89
Hb	g/dl	12-18	8,2	10,4
HCT	%	37-55	33,6	43,3
MCV	fL	60-77	68,1	73,5
MCH	Pg	19.5-24.5	16,1	17,7
MCHC	g/dl	31-34	24,4	24
PLT	10 <sup>3</sup> /μL	200-500	73	126
<b>Kimia klinik</b>				
Ure	mg/dL	10-20	4	
Cre	mg/dL	1-2	0,4	
ALT	U/L	8.2-57.3	22	
ALP	U/L	10.6-100.7	65	
Total Bil	mg/dL	0.07-0.61	0,3	
Total Prot	g/dL	5.4-7.5	9,2	
Alb	g/dL	2.6-4.0	2,1	
Glob	g/dL	2.7-4.4	7	
Ratio A/G		0.6-1.1	0,30	
Gluk	mg/dL	60-100	87	
Amil	U/L	269-1462	571	
Na	mmol/L	140-153	138	
K	mmol/L	3.8-5.6	4	
Ca	mg/dl	8.7-11.8	9,7	
P	mg/dL	2.6-6.8	3,4	

The surgical action performed was regional mastectomy. Mastectomy is surgical removal of the affected mammary glands as a way to minimize the spread of tumor cells. In the surgical procedure of removal of mammary gland

tumor (mastectomy) there are several techniques based on the location of the tumor. These are; Regional mastectomy, Unilateral mastectomy, bilateral mastectomy, and simple mastectomy [9]. In this case we carried out regional mastectomy by removing the left 3rd to the 5th mammary glands.

14 days post surgery, blood test (table 1) shows the number of PMN cells, erythrocytes and PCV in normal range. This suggests a decreased in inflammatory response and infection in the area of mammary gland tumors. There was an increased in platelet count when compared with a first-day blood test, although it still underwent thrombocytopenia. histopathological results of mammary gland tumors seen proliferation of the ductus with cuboid epithelium (Figure 3A). Cuboid epithelial cells in mammary duct tumors are seen multinuclei, pleomorphic with a prominent nucleolus and with basophilic cytoplasm (Figure 3B)

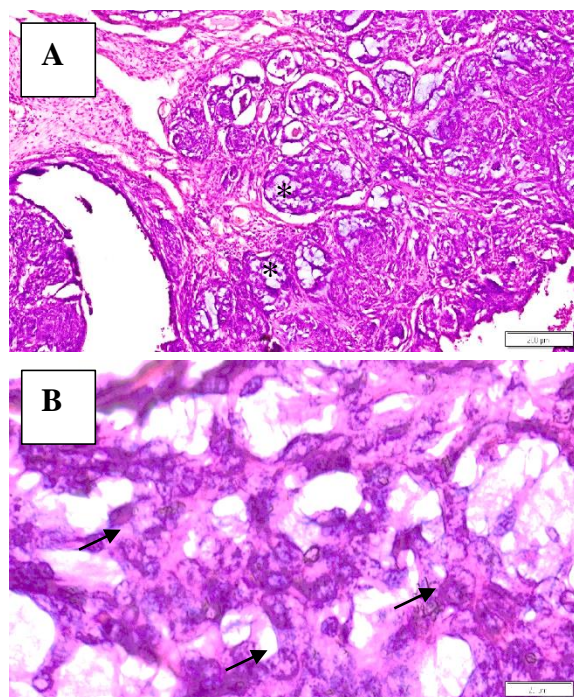


Figure 3. (A) The histopathological features of ductus-type mammary gland tumors are characterized by ductal proliferation with cuboid epithelium(\*). Haematoxylin and Eosin staining, 40X. (B) Cuboid epithelial cells in the mammary duct tumors show multinuclei, pleomorphic with a prominent nucleolus and accompanied by basophilic cytoplasm (arrows). Haematoxylin and eosin staining, 400X.

From Casey's history it was noted she had never been pregnant or been mated. The case of mammary tumors in this case might be caused by a hormonal disorders such as psuedopregnancy follow eustrus. According to Morris and Dobson<sup>1</sup>, continuous estrus without mating and pregnancy can cause vasodilation of blood vessels due to

increased estrogen hormone. As a result, the organs that are associated with reproduction; for example the mammary glands, will be exposed to excessive estrogen hormone, thus increasing the rate of proliferation of mammary gland cells that may cause the growth of the uncontrolled cells that become tumors.

Casey's age increases her risk to develop mammary gland tumors [10]. Also according to some studies, breeds such as Doberman, Spaniel breeds, German Shepherd and Boxer have increased risk of mammary glands tumors.

Avoidance of this disease requires vigilance on the part of animal owners. If there is no desire to be reproduce, it would be better to neuter bitches to prevent this disease. Dogs sterilized before their first estrus cycle have greatly reduced their risk of developing mammary cancer. The risk of developing a mammary tumor, (of which approximately 50% are malignant), is close to 0% in dogs that have been sterilized before their first estrus and increases to 26% for dogs spayed after their second estrus [3].

## CONCLUSION

Based on the results of a physical examination and a CBC investigator, blood chemistry and X-ray Casey's dog was diagnosed mammary gland tubulocarcinoma. The treatment was conducting a regional surgical mastectomy.

## ACKNOWLEDGMENTS

Thanks to the team of veterinary doctors who are involved in the treatment of this case. This research has been supported by Teaching Animal Hospital, University of Brawijaya, Malang, Indonesia.

## REFERENCES

- [1] Morris J. dan Dobson J. 2001. Skletal system. In: Small Animal Oncology. Oxford:Blackwell Science.
- [2] Moulton JE: Tumors of the mammary gland. In JE Moulton, editor: Tumours in domestic animals, ed 3, Berkeley, 1990, University of California Press.
- [3] Perez Alenza MD, Pena L, del Castillo N et al: Factors influencing the incidence and prognosis of canine mammary tumours, J Small Anim Pract 41:287, 2000.
- [4] Donnay I, Rauis J, Devleeschower N et al: Comparison of estrogen and progesterone receptor expression in normal and mammary tissues from dogs, Am J Vet Res 56:1188, 1995.
- [5] Stovring M, Moe L, Glattre E: A population-based case-control study of canine mammary tumors and clinical use of medroxyprogesterone acetate, Acta Pathologica Microbiologica Immunologica Scandinavica 105:590, 1997.
- [6] Steven L Stockham and Michael A Scott. 2008. *Fundamentals of Veterinary Clinical Pathologi 2<sup>nd</sup>*. Blackwell publishing. USA
- [7] Dasenbrock, H. H., Devine, C. A., Liu, K. X., Gormley, W. B., Claus, E. B., Smith, T. R. and Dunn, I. F. (2016), Thrombocytopenia and craniotomy for tumor: A National Surgical Quality Improvement Program analysis. *Cancer*, 122: 1708-1717.
- [8] Letimer Kenneth. 2011. *Duncan & Prasse's veterinary laboratory medicine: clinical pathology 5<sup>th</sup> ed*. John Wiley & Sons, Inc.
- [9] Fossum, Theresa. 2007. *Small Animal Surgery 3rd Edition*. Mosby Elsevier: Missouri, USA.
- [10] Egenvall, A., Bonnett, BN., Ohagen, P., Olson, P., Hedhammar, A. & von Euler, H. 2005. Incidence of and survival after mammary tumors in a population of over 80,000 insured female dogs in Sweden from 1995 to 2002. *Prev Vet Med.* 69(1-2): 109-27.