

***Streptococcus agalactiae* Associated with "Dark Body" Disease on Snakeskin Gourami Farmed in the Mekong Delta, Vietnam**

Tu Thanh Dung¹, Quach Van Cao Thi^{2*}, Nguyen Bao Trung¹

¹College of Aquaculture and Fisheries, Cantho University, Cantho City, Vietnam

²Faculty of Applied Biological Sciences, Vinh Long University of Technology Education, Vinh Long City, Vietnam

ARTICLE INFO

Article history:

Received October 30, 2023

Received in revised form December 4, 2023

Accepted December 15, 2023

KEYWORDS:

antibiogram,

dark body,

LD₅₀, snakeskin gourami,

Streptococcus agalactiae

ABSTRACT

Streptococcosis, due to *Streptococcus agalactiae*, has become a serious challenge for aquaculture around the world. Therefore, the main purpose of this work was to confirm the etiological agent that caused "dark body" disease in snakeskin gourami (*Trichogaster pectoralis*) cultured in the Mekong Delta, Vietnam. Infected fish displayed clinical signs, including anorexia, lethargic swimming on the water surface, corneal opacity, and hemorrhage in the base of the fin. Remarkably, abnormal black coloration on the body and serious hemorrhage at the base of the pectoral fin, and on the body were found in infected fish. In total, 75 bacterial strains were isolated from different diseased fish farms. Based on morphological and physiological characteristics, the API 20 Strep test, and 16S rRNA sequence analysis, the result illustrated that the bacterial isolates were identified as *S. agalactiae*. Additionally, antibiotic sensitivity testing revealed that all the *S. agalactiae* isolates were sensitive to amoxicillin, rifampicin, clarithromycin, erythromycin, doxycycline, cephalixin, novobiocin, and sulfamethoxazole-trimethoprim. Interestingly, *S. agalactiae* strains were only resistant to gentamycin in this study. Two strains, SRT41 and SRT43, carried out an experimental challenge with concentrations from 10⁴ to 10⁷ CFU/ml in healthy snakeskin gourami, and the LD₅₀ values of the isolates, SRDT41 and SRDT43, were determined to be 2.15 × 10⁵ and 3.59 × 10³ CFU/ml, respectively, after 7 days. To our knowledge, this is the first report of *S. agalactiae* derived from intensively cultured snakeskin gourami in the Mekong Delta, Vietnam.

1. Introduction

Trichogaster pectoralis, also known as snakeskin gourami or "lo tho fish", is a freshwater fish that is popularly distributed in South Asian and Southeast Asian countries, such as Thailand, Bangladesh, Laos, India, Indonesia, Malaysia, and Cambodia (Phong 2014). In Vietnam, this species previously lived naturally in some southern provinces of the Mekong Delta, such as Kien Giang, Bac Lieu, Can Tho, Soc Trang, and Ca Mau (Long *et al.* 2014). Due to accessory respiratory organs, it can tolerate a pH range between 6 and 8, a temperature range of 22 to 28°C, and a high salinity level in waters with low dissolved oxygen and high organic loads (Long *et al.* 2014; Mai *et al.* 2016). In addition, their food sources are diverse, including

zooplankton, crustaceans, and insect larvae (Tacon *et al.* 2011). Especially, *T. pectoralis* has a good taste and is traditionally a favorite dried fish source in Vietnam (Muoi and Truc 2008; Truc *et al.* 2009; Minh *et al.* 2019). The most expensive farmed freshwater fish is the snakeskin gourami, which typically sells for between USD 2.5 and 3.5 per kilogram in 2014, as opposed to USD 1.0 to 1.2 per kilogram for pangasius catfish or USD 1.5 to 1.6 per kilogram for red tilapia (Phong 2014). Currently, fish are farmed mainly in Dong Thap and Ca Mau provinces, with an area of nearly 450 ha and an output of over 4,500 tons (personal information).

Globally, commercial breeding of snakeskin gourami fish has grown significantly in recent years (Gustiano *et al.* 2022). However, due to the increasing level of intensive farming with high stocking densities, epidemics occur more frequently, are difficult to control, and cause huge damage to fish (Pulkkinen *et al.* 2010; Sundberg *et al.* 2016; Ndashe *et al.* 2023). Diseases

* Corresponding Author

E-mail Address: thiqvc@vlute.edu.vn

occurring in fish as well as other aquatic animals are mainly caused by bacteria, fungi, parasites, and viruses (Ziarati *et al.* 2022). Importantly, bacterial diseases are becoming more common and causing a lot of damage to fish farming (Irshath *et al.* 2023). Among the groups of pathogenic bacteria, *Streptococcus* species occur in many species of farmed fish around the world. This bacterial genus, gram-positive bacteria, causes streptococcosis with significant mortality in farmed fish, economic losses to the aquaculture industry, and public health issues (Van Doan *et al.* 2022). Until now, streptococcosis has been caused by crucial bacteria, including *S. agalactiae*, *S. iniae*, *S. difficilis*, *S. shiloi*, *S. difficile*, and *S. dysgalactiae* (Abdelsalam *et al.* 2013; Pradeep *et al.* 2016). Streptococcosis has been estimated to cause a yearly loss of 250 million USD worldwide (Amal and Zamri-Saad 2011). Exophthalmia, erratic swimming, pale gills, an opaque cornea, external hemorrhages, an enlarged spleen, ascites in abdominal cavities, and a discolored liver are some of the clinical indications of streptococcosis (Leal *et al.* 2019).

To date, many important cultured shrimp and fish species in the Mekong Delta and the other regions of Vietnam have identified their causative agents, including whiteleg shrimp (Khoang *et al.* 2020), striped catfish (Hoa *et al.* 2021), tilapia (Phuoc *et al.* 2019), snakehead fish (Dung *et al.* 2019), and grass carp fish (Hoai *et al.* 2022). However, reports on diseases in snakeskin gourami fish around the world as well as in Vietnam are relatively few. In Thailand, snakeskin gourami fish were simultaneously infected with a novel Chlamydia-like organism (CLO) and a *Myxozoa* parasite

called *Henneguya* sp. (Dinh-Hung *et al.* 2022). Soon after, the first report of *Posthodiplostomum* sp. metacercariae associated with "lumpy skin disease" from snakeskin gourami was also recorded by Dinh-Hung *et al.* (2023a). Especially the newest findings of Dinh-Hung *et al.* (2023b) illustrated that *S. suis* is the new causative agent in snakeskin gourami fish. Generally, previous research has not yet recorded cases of snakeskin gourami infected with *S. agalactiae*. Meanwhile, many infected fish were reported, including tilapia (Al-Harbi 2016; Alazab *et al.* 2022), golden pompano (Amal *et al.* 2012), pampus argenteus (Duremdez *et al.* 2004), climbing perch (Klingklib and Suanyuk 2017), scortum barcoo (Liu *et al.* 2014), and mullet (Chu *et al.* 2016). Therefore, this study aims to identify, elucidate pathological characteristics, and assess the antibiotic susceptibility of *S. agalactiae*, which causes dark body disease in snakeskin gourami fish.

2. Materials and Methods

2.1. Collection of Fish Samples

Snake gourami fish samples were collected from 23 intensive farming ponds with signs of black body disease in Dong Thap, An Giang, and Ca Mau province (Figure 1). Each pond collected 5–10 infected fish and 2 healthy fish (control). Samples were collected during the period from August to October 2022. Samples were isolated from farming households and analyzed at the laboratory of the Faculty of Aquatic Pathology, College of Aquaculture, Can Tho University.




Figure 1. (A) Location of fish samples (red circle), (B) diseased fish, swimming lethargically (red arrow) for the isolation of *S. agalactiae*

2.1.1. Bacterial Isolation

Liver, kidney, spleen, brain, and blood samples characterized by hemoperitoneum, hepatomegaly, splenomegaly, and an enlarged kidney were collected to isolate *S. agalactiae* from sick fish by post-mortem. The bacterial isolation was processed according to Frerichs and Millar (1993). Briefly, swabs of the liver, kidney, brain, eyes, and blood of each fish were taken aseptically and streaked onto both 5% sheep blood agar and brain heart infusion agar. The plates were then incubated at 28°C for 24–48 hours for the observation of colony morphology. The inspected colonies (white, round, and opaque) were subcultured on the same agar plates. Finally, pure isolates were kept at -80°C in BHI broth with 15% glycerol (v/v) for further studies.

2.2. Bacterial Characteristics

Basic morphological, physiological, and biochemical characteristics of bacteria cultured on BA media were examined, including Gram staining, motility, oxidase, catalase, and the oxidation/fermentation (O/F) reaction. In BHI medium, the isolates' capacity to develop on medium supplemented with 6.5% NaCl, pH 9.6, and 60°C was examined. To test for hemolytic activity, bacteria were grown on Blood Agar Base media and then incubated for 18 to 24 hours at 37 °C with 5% (v/v) sheep blood. These elements were implemented in accordance with Buller's (2004), Frerichs and Millar's (1993), and Cowan and Steel's (1993) manuals (Barrow and Feltham 1993). Finally, *S. agalactiae* was identified in accordance with the manufacturer's instructions using the API 20 Strep Kit (bioMerieux, France).

2.3. Identification by Molecular Biology

Representative *S. agalactiae* isolates were utilized in the PCR procedure for molecular identification. With slight modifications, bacterial DNA was extracted in accordance with Moore *et al.* (2004). In brief, bacteria were grown for 24 hours at 28°C with 100 rpm of agitation in BHI broth medium (Brain heart infusion broth). The pellets obtained by centrifuging cell suspensions at 4,500 rpm for 5 minutes at 4°C were resuspended in TE buffer (10 mM Tris-HCl, 1 mM EDTA, pH 8.0). The extraction of the suspension involved centrifuging it at 15,000 rpm for five minutes while using an equal proportion of phenol:chloroform:isoamyl alcohol (25:24:1). A separate 2 ml Eppendorf tube was used to transfer the DNA-containing upper aqueous phase, and 0.7 µL of

isopropanol was added. Centrifugation for 20 minutes was used to recover the aqueous phase, and ethanol was used to precipitate the genomic DNA. Using a spectrophotometer, the extracted DNA was examined for purity and concentration at 260 and 280 nm.

S. agalactiae were identified by PCR with the universal primers 27F: 5'-AGAGTTTGATCMTGGCTCAG-3' and 1492R: 5'-TACGGYTACCTTGTTACGACTT-3' (Heuer *et al.* 1997) for amplifying 16S rRNA gene fragments. The PCR reaction mixture consisted of sterilized water, 1X PCR buffer, MgCl₂ (25 mM), 0.1 mM of each dNTPs, forward and reverse primers (10 µM each), Taq DNA polymerase (2.5 unit/µL), and template DNA. The electrophoresis for the analysis of the amplification products was run with 2% agarose gel in 1X TAE. The electrophoresis result was read and photographed using BioRad UV 2000. PCR products of 1,500 bp were sequenced at Macrogen Company, Korea (www.macrogen.com).

2.4. Experimental Challenge

Healthy snakeskin gourami fish (8±1 g body weight) were purchased at hatcheries in Can Tho City. Fish were maintained in a composite tank with a volume of about 500 L to get used to the experimental conditions for 7–14 days. Fish are fed with pellets based on the fish's needs. Fish are tested for parasites, bacteria and fungi before infection to ensure the fish are healthy.

2.4.1. Bacteria for the Challenge Test

Two strains, SRDT41 and SRDT43, were isolated from the "dark body" snakeskin gourami fish in two different ponds. Bacteria were grown in BHI broth on a shaker at 28°C for 24–48 hours, centrifuged at 4°C at 13,000 rpm for 10 minutes, rinsed with physiological saline solution (0.85% NaCl), and centrifugation repeated three times. Bacterial density was determined by spectrophotometer at 600 nm with OD₆₀₀ = 1±0.02 equivalent to a bacterial density of 10⁸ CFU/ml. The bacterial solution was serially diluted to 10⁴, 10⁵, 10⁶, and 10⁷ CFU/ml for challenge test (Table 1).

2.4.2. Experimental Designs

Experimental fish were injected bacterial density (shown in Table 1) into the abdominal cavity with a dose of 0.1 ml/fish. The control treatment was injected with sterile physiological saline (0.85% NaCl) at the same dose. Three replications were

Table 1. Bacterial density used for infection experiments

Treatment group	Number of fish	Isolates	Challenge dose (CFU/ml)
1	10	<i>S. agalactiae</i> SRĐT43	10 ⁴
2	10		10 ⁵
3	10		10 ⁶
4	10		10 ⁷
5	10	<i>S. agalactiae</i> SRĐT41	10 ⁴
6	10		10 ⁵
7	10		10 ⁶
8	10		10 ⁷
9	10	Control (0.85% NaCl)	No bacteria

used in a randomized design for each experiment. The mortality rate and clinical signs were recorded during the experiment. Lethargic or newly dead fish were re-isolated and re-identified from the liver, kidney, spleen, brain, and blood on TSA medium. The LD₅₀ value was calculated according to the method of Reed and Muench (1938).

2.5. Antibiogram

Antibiogram was performed according to the standards of the Clinical and Laboratory Standards Institute (CLSI 2020) on Mueller-Hinton Agar medium (MHA, Meck, Germany) with 10 antibiotics as follows: amoxicillin (AMC/10 µg), cephalexin (CL/30 µg), florfenicol (FFC/30 µg), doxycycline (DO/30 µg), erythromycin (E/30 µg), gentamycin (CN/10 µg), clarithromycin (CLR/15 µg), rifampicin (RD/30 µg), novobiocin (NV/5 µg), and sulfamethoxazole-trimethoprim (SXT/25 µg) (Oxoid, UK). Briefly, pure colonies are inoculated into 5 ml of BHI broth. The suspensions were then adjusted to 10⁸ CFU/ml by comparison to the McFarland standard. The suspensions were spread on MHA medium containing 5% defibrinated sheep blood. *Escherichia coli* (ATCC 25922) was tested as quality control. Finally, the susceptibility and resistance of isolates were then determined according to the manufacturer's instructions and the criteria of the Clinical and Laboratory Standards Institute (CLSI 2020).

2.6. Data Analysis

Descriptive statistics were used to determine antimicrobial resistance and cumulative mortality. The BLASTn tool was used to compare the sequence similarity of bacterial strains with sequences in the NCBI database (National Center for Biotechnology Information). Using MEGA6 (Molecular Evolutionary Genetics Analysis) software and the neighbor-joining

algorithm (Saitou and Nei 1987), the phylogenetic tree illustrating the genetic links between bacterial strains was created (Tamura *et al.* 2013).

3. Results

3.1. Clinical Signs

Dark body disease in snakeskin gourami fish can appear at all stages of the fish. Infected fish exhibited the following clinical signs: anorexia, lethargic swimming on the water surface (severely sick fish showed signs of circular swimming), and corneal opacity (Figure 2C). Notably, abnormal black coloration on the body and distended abdomen (Figure 2B) and serious hemorrhage at the base of the pectoral fin and on the body (Figure 2C) were found in diseased fish. Internally, sick fish did not show any abnormalities in internal organs compared to healthy fish (except for the slightly pale livers, kidneys, and spleens) and abdominal cavities with red fluid (Figure 2D).

3.2. Bacterial Isolation

The study isolated 75 strains from 123 fish samples. Bacteria were mostly isolated from the liver (35/75 isolates, 46.67%), kidney (15/75 isolates, 20%), spleen (10/75 isolates, 13.33%), brain (8/75 isolates, 10.67%), and blood (7/75 isolates, 9.33%).

3.3. Morphological, Physiological, and Biochemical Characteristics

All the representative colonies displayed small and white round colonies on BHI agar (Figure 3A). A single colony has a diameter between 0.5 and 1.0 mm. Isolated bacterial isolates are gram-positive cells with round cells (cocci) in pairs or chains when observed under the microscope (Figure 3B). They were non-hemolytic, non-motile, and negative for oxidase, catalase, and O/F (Table 2). The isolated isolates could grow between 15 and 42°C, but not at 10°C. Additionally, the isolates of *S. agalactiae* under study thrived in a medium containing 5% NaCl but not 6.5%.

3.4. Identification by the API 20Strep Kit

The results from the API 20 Strep Kit revealed 90% S6FC3 isolate similarity to *S. agalactiae*. This isolate exhibited positive results for Voges-Proskauer, β-glucuronidase, alkaline phosphatase, leucine aminopeptidase, arginine dihydrolase, D-ribose, D-trehalose, and glycogen; the rest were negative, including hydrolysis of hippurate, esculin, pyrrolidonyl arylamidase, α-galactosidase, β-galactosidase,




Figure 2. Clinical signs of snakeskin gourami infected with *S. agalactiae* (A) Healthy fish with normal symptoms, (B) infected fish with a black body and distended abdomen, (C) dead fish displayed gross signs of hemorrhage and corneal opacity (arrow), (D) abdominal cavities with red fluid

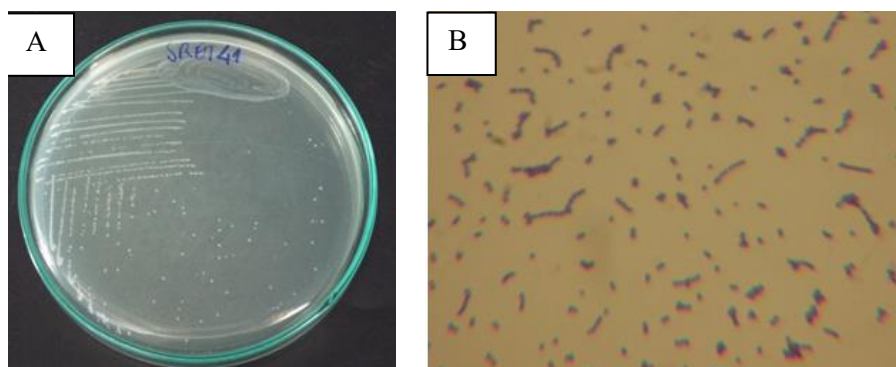


Figure 3. (A) Colony of *Streptococcus* sp. on TSA medium, (B) gram staining

Table 2. Morphological, physiological, and biochemical features of the SRĐT41 and SRĐT43 isolate

Reaction	Isolate SRĐT41	Isolate SRĐT43	<i>S. agalactiae</i> *
Gram stain	+	+	+
Cell morphology	Cocci, chain	Cocci, chain	Cocci, chain
Colony diameter	0,1 -1 mm	0,1 -1 mm	
Color	Opalescent	Opalescent	
Growth day	24-48 hours	24-48 hours	
Hemolysis	Non-haemolytic	Non-haemolytic	Non-haemolytic
Catalase	-	-	-
Oxidase	-	-	-
O/F	-/-	-/-	
Motility	-	-	-
Growth in 6.5% NaCl	-	-	-

(+) positive reaction, (-) negative reaction, *Niu et al. (2020)

Table 2. Continued

Reaction	Isolate SRĐT41	Isolate SRĐT43	<i>S. agalactiae</i> *
Growth at pH 9.6	-	-	-
Growth at 10°C	-	-	-
Growth at 15°C	+	+	+
Growth at 45°C	+	+	+
Voges-Proskauer	+	+	+
Hydrolysis of hippurate	-	-	+
Esculin	-	-	-
Pyrrolidonyl arylamidase	-	-	-
α-galactosidase	-	-	-
β-glucuronidase	+	+	-
β-galactosidase	-	-	-
Alkaline phosphatase	+	+	+
Leucine aminopeptidase	+	+	+
Arginine dihydrolase	+	+	+
D-ribose	+	+	+
L-arabinose	-	-	-
D-mannitol	-	-	-
D-sorbitol	-	-	-
D-lactose	-	-	-
D-trehalose	+	+	+
Inulin	-	-	-
D-raffinose	-	-	-
Starch	-	-	-
Glycogen	+	+	-

(+) positive reaction, (-) negative reaction, *Niu *et al.* (2020)

β-galactosidase, L-arabinose, D-mannitol, D-sorbitol, D-lactose, inulin, D-raffinose, and starch (Table 2).

3.5. Identification of *S. agalactiae* by PCR

The PCR result showed that all tested bacterial isolates were positive for a DNA band at the 1,500 bp position (Figure 4). The Blast results showed that isolate SRĐT41 had 100% homology to *S. agalactiae* strain B14S (OR342563.1), *S. agalactiae* strain 023-RIA1 (OP290419.1), *S. agalactiae* strain DFI-10 (MZ921512.1), and *S. agalactiae* strain strain E7X (OR342567.1). On the contrary, isolate SRĐT43 showed 99.96% similarity to *S. agalactiae* strain G_35 (MT626753.1), *S. agalactiae* strain Israel1 (MK517599.1), *S. agalactiae* strain ATCC 51487 (KU561093.1), and *S. agalactiae* strain GXYL3 (KT328485.1).

Based on the 16S rRNA sequences of isolates SRĐT41 and SRĐT43 and the homologous sequences of other strains of *S. agalactiae* and *S. iniae* (outgroup) in the GenBank, a phylogenetic tree was constructed (Figure 5). In this study, isolate SRĐT41, together with *S. agalactiae* (OR342563.1), *S. agalactiae* (OP290419.1), *S. agalactiae* (MZ921512.1), and *S. agalactiae* (OR342567.1), formed similar cluster

(Figure 5). Meanwhile, isolate SRĐT43 had a closed relationship with *S. agalactiae* (KT328485.1), *S. agalactiae* (MT626753.1), *S. agalactiae* (KU561093.1), and *S. agalactiae* (MK517599.1). To sum up, two isolates, SRĐT41 and SRĐT43, were determined to be *S. agalactiae* based on morphology, API 20 Strep tests, and 16S rRNA sequence analysis results.

3.6. Experimental Tests

The infection results on snakeskin gourami showed clinical signs like those of snakehead fish with "dark body" disease in ponds. Fish died first at densities of 10^5 – 10^7 CFU/ml after 2 days of infection. Fish died in all treatments except the control treatment injected with physiological saline (0.85% NaCl). After 7 dpi, fish in the treatments died at a rate of 5-75%. After 14 dpi, the fish mortality rate for the two susceptible bacterial strains at a density of 106 CFU/mL was 65% and 75%, respectively (Figure 6). Re-isolation of bacteria from infected experimental fish gave results like those of bacteria causing "dark body" disease in the wild. The LD₅₀ values of isolates SRĐT41 and SRĐT43 were determined to be 2.15×10^5 and 3.59×10^3 CFU/ml, respectively, after 7 dpi.

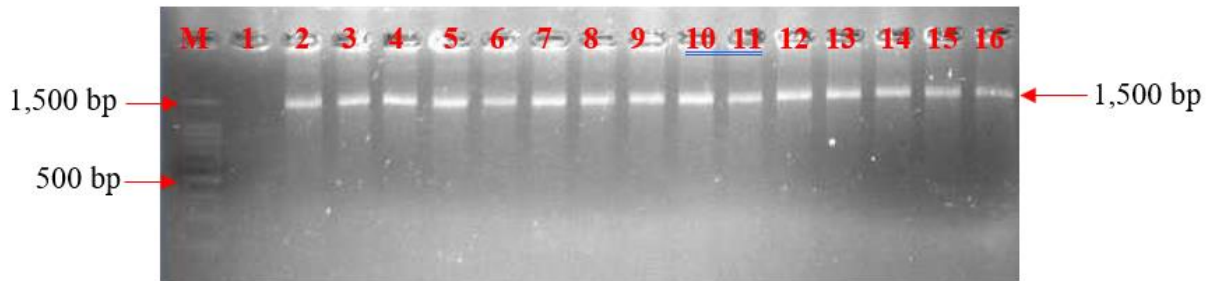


Figure 4. Detection of *S. agalactiae* isolates by PCR reaction. M: 100 bp ladder (Invitrogen); Lane 1: Negative control; Lane 2–16: isolates SRĐT2, SRĐT2, SRĐT3, SRĐT10, SRĐT12, SRĐT14, SRĐT24, SRĐT26, SRĐT30, SRĐT31, SRĐT34, SRĐT35, SRĐT40, SRĐT41, and SRĐT43, respectively




Figure 5. Phylogenetic analysis of *S. agalactiae* recovered from snakeskin gourami in this study and isolates retrieved from GenBank (bootstraps of 1,000 replicates were performed at the branch node; *S. iniae* (LC378582.1) was used as an outgroup)

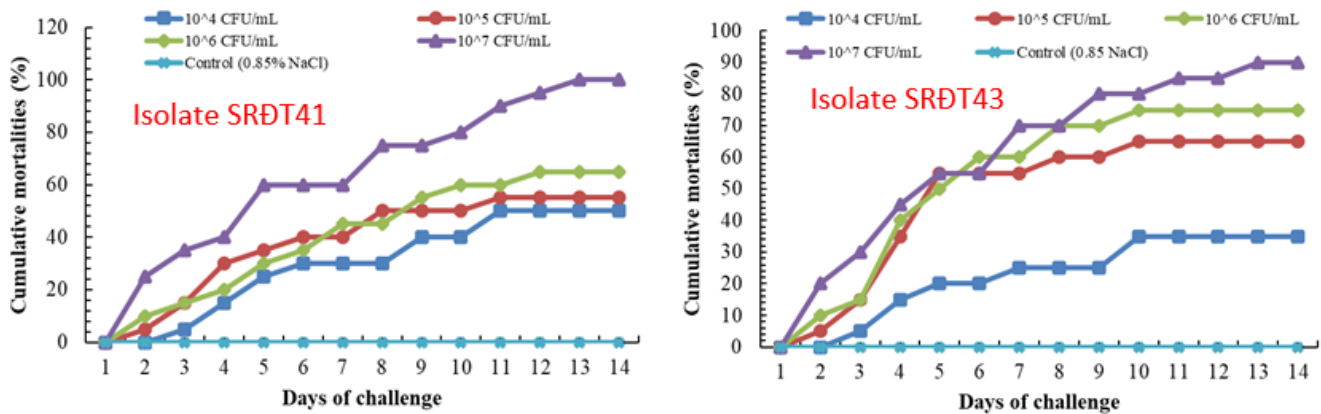


Figure 6. Cumulative mortality of *S. agalactiae* infection in snakeskin gourami

3.7. Antibiogram

As shown in Table 3, all the *S. agalactiae* isolates were sensitive to amoxicillin, rifampicin, clarithromycin, erythromycin, doxycycline,

cephalexin, novobiocin, and sulfamethoxazole-trimethoprim. Remarkably, 100% of *S. agalactiae* isolates in this study showed resistance to gentamycin.

Table 3. Antibiotic susceptibility of isolated isolates of *S. agalactiae*

Antibiotics	Isolate SRĐT23	Isolate SRĐT41	Isolate SRĐT43
Amoxicillin (25µg)	S	S	S
Cephalexin (30µg)	S	S	S
Doxycycline (30µg)	S	S	S
Florfenicol (30µg)	S	S	S
Erythromycin (15µg)	S	S	S
Clarithromycin (15µg)	S	S	S
Gentamycin (10µg)	R	R	R
Rifampicin (30µg)	S	S	S
Novobiocin (5µg)	S	I	S
SXT (25 µg µg (1,25/23,75µg))	I	S	S

SXT: sulfamethoxazole-trimethoprim; S: sensitive; R: resistance; I: intermediate

4. Discussion

Streptococcal infections have caused huge economic damage to aquaculture activities (Austin and Austin 2016). *S. iniae*, *S. difficile*, *S. agalactiae*, *S. parauberis*, *S. dysgalactiae*, and *S. shilo* are the main species that infect fish (Eldar *et al.* 1994; Buchanan *et al.* 2008; Netto *et al.* 2011; Nho *et al.* 2013; Asencios *et al.* 2016; El-Noby *et al.* 2021). The present study isolated 75 strains from 123 fish samples. The isolated isolates mostly originated from internal organs (liver, kidney, spleen, brain, and blood) based on their morphological, physiological, and biochemical characteristics. To date, there have been no findings of *S. agalactiae* being linked with disease outbreaks in fish. To the best of our knowledge, this is the first time that *S. agalactiae* has been confirmed as a new pathogen causing a disease outbreak in cultivated snakeskin gourami. In general, the phenotypic traits of isolated bacterial isolates are mostly consistent with the descriptions of Buller (2004) and Wongsathein *et al.* (2018) on *S. agalactiae* (Table 2). Bacterial isolates obtained from diseased snakeskin gourami fish were gram-positive, non-motile, negative for oxidase, and catalase. They are not capable of growing at 10°C, pH 9.6, and 6.5% NaCl but can survive at 10°C, and 45°C. Hemolytic activity tests showed that all bacterial isolates in this study are non-hemolytic, which is different from the study of Wongsathein *et al.* (2018). According to Abuseliana *et al.* (2010) and Buller (2014), *S. agalactiae* may or may not be hemolytic. In the present study, the identification results using the API 20 Strep kit showed that the biochemical and physiological characteristics of the identified bacterial

strain were similar to those of *S. agalactiae* described by Buller (2014), except that the glycogen indicator was negative compared to Buller's results, which were positive (Table 2). The existence of different types of *Streptococcus* species emphasizes the difficulties of definitive identification based on phenotypic traits alone. For this reason, numerous publications advise using molecular methods like PCR to specifically identify this bacterium (Jimenez *et al.* 2011) in combination with morphological, physiological, and biochemical data (Wongsathein 2012). In the current investigation, the PCR assay verified and produced bands with a 1,500 bp amplification for isolated strains of *S. agalactiae* (Figure 4).

Streptococcosis has become a significant issue for the aquaculture industry around the world (Mishra *et al.* 2018). Within this, the species *S. agalactiae* is the most dominant worldwide (Sheehan *et al.* 2009). The *S. agalactiae*-infected fish are characterized by loss of appetite, exophthalmia, eye hemorrhage, corneal opacity, distended abdomen, curvature of the spinal cord, erratic swimming, stiffness, and bleeding on the base of the fins (Yanong and Francis-Floyd 2002). The diseased snakeskin gourami from the farm exhibited anorexia, lethargic swimming on the water surface, an abnormal black color on the body (Figure 2B), hemorrhage at the base of the fin, especially serious hemorrhage and hemorrhage on the body (Figure 2C). The experimental challenge in this study revealed that the isolate reproduced the disease with clinical and pathological signs similar to those seen during a natural infection and seen during other streptococcal infections. The clinical signs that *S. agalactiae* causes in snakeskin gourami are similar to the typical pathological lesions that other fish species experience when streptococcal infections occur (Sheehan 2009; Oanh and Phuong 2012; Wongsathein *et al.* 2019). Consistent findings were also achieved in the study of Dinh-Hung *et al.* (2023b), who reported that lethargy, swimming disorders, loss of appetite, corneal opacity or exophthalmos, skin hemorrhages or erosions, and internal signs such as an enlarged liver and splenomegaly were found in *S. suis*-infected snakeskin gourami fish.

S. agalactiae belongs to the group of positive-gram bacteria and is one of the causative agents of black body marks in many freshwater, brackish, and saltwater fish species (Inglis *et al.* 1993; Yanong and Francis-Floyd 2002). In addition to snakeskin gourami fish, this bacterium has caused serious

damage to tilapia (*Oreochromis* sp.) farming in many countries around the world, with high mortality rates of over 50% (Yanong and Francis-Floyd 2002). In this investigation, the cumulative morbidity ranged from 5-75% (Figure 6), and the LD₅₀ values of SRĐT41 and SRĐT43 were determined to be 2.15×10^5 and 3.59×10^3 CFU/ml, respectively. Previously, many studies have documented LD₅₀ values for other *Streptococcus* species varying from 3.2×10^4 to 2.5×10^5 CFU/fish in Asian sea bass (Bromage *et al.* 1999) infected with *S. iniae*; from 2.45×10^8 to 5.54×10^8 CFU/fish in crucian carp infected with *S. dysgalactiae* (Yang and Li 2009); from 1.8×10^6 to 3.6×10^7 CFU/fish in *O. niloticus* infected with *S. agalactiae* (Wang *et al.* 2013; Kayansamruaj *et al.* 2014) and from 5.1×10^5 to 6.4×10^5 CFU/fish in *Acipenser baerii* (Deng *et al.* 2017). From the results of this present study, it was found that *S. agalactiae* has lower virulence in snakeskin fish than in other fish species infected with *Streptococcus*. In fact, the virulence and pathogenesis of streptococci differ greatly depending on bacterial species, infection routes, fish stage and species, and environmental factors (Yanong and Francis-Floyd 2002; Buchanan *et al.* 2008; Kayansamruaj *et al.* 2014; Wongsathein *et al.* 2019). According to Dinh-Hung *et al.* (2023b), both small and big fish experienced mortality in excess of 50% even at a low dose (1.2×10^5 CFU/fish); however, the LD₅₀ (median lethal dose) was not determined in this study. Furthermore, a recent study by Pulpipat *et al.* (2023) revealed that three representative isolates of *S. agalactiae* isolated from intensively farmed snakeskin gourami demonstrated high mortality exceeding 60%.

Antibiotics have been the main solution to control bacterial infections in aquatic animals in Vietnam and many other countries around the world (Binh *et al.* 2018; Serwecińska 2020). However, incorrect antibiotic use can result in germs that are resistant to them, which is a serious issue that could have an impact on human health (Miranda *et al.* 2018; Fry *et al.* 2020). Previous studies revealed that a variety of bacteria that cause disease in many aquatic animals exhibit resistance to classes of antibiotics (Pepi and Focardi 2021; Yuan *et al.* 2023). In the present work, ten commonly used antimicrobial agents (amoxicillin, florfenicol, doxycycline, gentamycin, erythromycin, clarithromycin, rifampicin, novobiocin, cephalixin, and sulfamethoxazole-trimethoprim) were chosen for the antibiotic sensitivity test as they are commonly used for the prevention and treatment of bacterial

diseases in fish and shrimp farms in Vietnam (Huong *et al.* 2021). Interestingly, the results revealed that all studied *S. agalactiae* isolates were susceptible to nine antimicrobial agents, including amoxicillin, rifampicin, clarithromycin, erythromycin, doxycycline, cephalixin, novobiocin, and sulfamethoxazole-trimethoprim (Table 3). These findings are consistent with Sapugahawatte *et al.* (2022), who reported that the *S. agalactiae* (also known as Group B *Streptococcus*, GBS) isolated from freshwater fish in Hong Kong Wet Markets were mostly antibiotic-sensitive, including vancomycin, linezolid, and levofloxacin (100% each), penicillin, and ciprofloxacin (99.5% each), clindamycin (98.5%), erythromycin (96.9%), minocycline, and tetracycline (94.3% each). In Thailand, similar results were found in the research by Wongsathein *et al.* (2018), who reported that *S. agalactiae* isolates recovered from farmed tilapia were susceptible to oxytetracycline, sulphamethoxazole-trimethoprim, enrofloxacin, amoxicillin, penicillin, and chloramphenicol. In contrast to the findings of the present study, Deng *et al.* (2019) reported that *S. agalactiae* isolates from diseased farmed tilapia fish in China showed resistance to erythromycin (42.9%), penicillin (35.7%), clindamycin (28.6%), enrofloxacin (35.7%), tetracycline (32.1%), gentamicin (28.6%), norfloxacin (28.6%), ofloxacin (14.3%), and doxycycline (7.14%). However, all the isolates were susceptible to vancomycin, cephalixin, and florfenicol. Recently, Pulpipat *et al.* (2023) revealed that some isolates of *S. agalactiae* were resistant to sulfamethoxazole-trimethoprim, doxycycline, and enrofloxacin. On the contrary, all the *S. agalactiae* were susceptible to amoxicillin and erythromycin. In Vietnam, research by Phuoc *et al.* (2019) showed that bacterial strains of *S. agalactiae* isolated from red tilapia (*Oreochromis* sp.) farmed in Thua Thien Hue are sensitive to the antibiotics oxacillin, amoxicillin, and streptomycin at a rate of 96.3%, 92.5%, and 63.9%, respectively. On the other hand, *S. agalactiae* bacterial strains from this report were resistant to ampicillin and tetracycline at a rate of 66.7% and 59.3%, respectively. Notably, only one isolate of *S. agalactiae* showed resistance to gentamycin. This result is in line with Reyes *et al.* (2019), who reported that all *S. agalactiae* isolates isolated from tilapia pond soil in the Philippines were susceptible to gentamicin, nalidixic acid, chloramphenicol, and tetracycline. Similarly, Deng *et al.* (2019) illustrated that 8/28 *S. agalactiae* isolates (28.6%) were resistant to gentamicin. Therefore, amoxicillin, rifampicin,

clarithromycin, erythromycin, doxycycline, and cephalixin can be used to treat black body disease in snakehead fish. However, farmers should only use antibiotics when absolutely necessary and must be cautious when using antibiotics in the treatment of diseases in aquatic animals. Importantly, to lessen the effects of *Streptococcus* infection in snakeskin gourami, additional active epidemiological surveillance and appropriate control measures should be put in place.

In conclusion, based on morphological and physiological characteristics, the API 20 Strep test, and 16S rRNA sequence analysis, the bacterial isolates were identified from the "dark body" snakeskin gourami fish. LD₅₀ value 7 dpi on two isolates, SRDT41 and SRT43, were 2.15×10^5 and 3.59×10^3 CFU/ml, respectively. Furthermore, all the *S. agalactiae* isolates were sensitive to amoxicillin, rifampicin, clarithromycin, erythromycin, doxycycline, cephalixin, novobiocin, and sulfamethoxazole-trimethoprim. Interestingly, isolated *S. agalactiae* strains were only resistant to gentamycin. The results of the study provide the necessary information for controlling dark body disease in snakeskin gourami fish in the future.

Acknowledgements

The authors express their special thanks to the the Faculty of Aquaculture and Fisheries, Can Tho, and University Vinh Long University of Technology Education for this research's implementation. Many grateful thanks are also given to all the snakeskin gourami farmers in the Mekong Delta and UV company for their kind help during fish sample collection.

References

Abdelsalam, M., Asheg, A., Eissa, A.E., 2013. *Streptococcus dysgalactiae*: an emerging pathogen of fishes and mammals. *Int. J. Vet. Sci. Med.* 1, 1-6. <https://doi.org/10.1016/j.ijvsm.2013.04.002>

Abuseliana, A., Daud H., Aziz S., Bejo S., Alsaid M., 2010. *Streptococcus agalactiae* the etiological agent of mass mortality in farmed red tilapia (*Oreochromis* sp.). *J. An. Vet. Adv.* 9, 2640-2646. <https://doi.org/10.3923/javaa.2010.2640.2646>

Alazab, A., Sadat, A., Younis, G., 2022. Prevalence, antimicrobial susceptibility, and genotyping of *Streptococcus agalactiae* in Tilapia fish (*Oreochromis niloticus*) in Egypt. *J. Adv. Vet. Anim. Res.* 9, 95-103. <https://doi.org/10.5455/javar.2022.i573>

Al-Harbi, A.H., 2016. Phenotypic and genotypic characterization of *Streptococcus agalactiae* isolated from hybrid tilapia (*Oreochromis niloticus* × *O. aureus*). *Aquaculture*. 464, 515-520. <https://doi.org/10.1016/j.aquaculture.2016.07.036>

Amal, M.N.A., Zamri-Saad, M., 2011. Streptococcosis in tilapia (*Oreochromis niloticus*): a review. *Pertanika. J. Trop. Agric. Sci.* 34, 195-206.

Amal M.N.A., Zamri-Saad M., Iftikhar A. R., Siti-Zahrah A., Aziel S., Fahmi S., 2012. An outbreak of *Streptococcus agalactiae* infection in cage-cultured golden pompano, *Trachinotus blochii* (Lacépède), in Malaysia. *J. Fish Dis.* 35, 849-852. <https://doi.org/10.1111/j.1365-2761.2012.01443.x>

Asencios, O.Y., Sanchez, B.F., Mendizabal, B.H., Pusari, H.K., Alfonso, O.H., Sayan, M.A., Figueiredo M.A.P., Manrique, W.G., Belo, M.A.A., Chaupe, N.S., 2016. First report of *Streptococcus agalactiae* isolated from *Oreochromis niloticus* in Piura, Peru: molecular identification and histopathological lesions. *Aquac Rep.* 4, 74-9. <https://doi.org/10.1016/j.aqrep.2016.06.002>

Austin, B., Austin, D.A., 2016. *Bacterial Fish Pathogens: Disease of Farmed and Wild Fish*. Springer International Publishing: Cham, Switzerland.

Barrow, I.G., Feltham, R.K.A., 1993. *Cowan and Steel's Manual for the Identification of Medical Bacteria*, third ed. Cambridge University Press, Cambridge.

Binh, V.N., Dang, N., Anh, N.T.K., Ky, L.X., Thai, P.K., 2018. Antibiotics in the aquatic environment of Vietnam: sources, concentrations, risk and control strategy. *Chemosphere*. 197, 438-50. <https://doi.org/10.1016/j.chemosphere.2018.01.061>

Bromage, E.S., Thomas, A., Owens, L., 1999. *Streptococcus iniae*, a bacterial infection in barramundi *Lates calcarifer*. *Dis Aquat Organ.* 36, 177-181. <https://doi.org/10.3354/dao036177>

Buchanan, J.T., Colvin, K.M., Vicknair, M.R., Patel, S.K., Timmer, A.M., Nizet, V., 2008. Strain-associated virulence factors of *Streptococcus iniae* in hybrid-striped bass. *Vet. Microbiol.* 131, 145-53. <https://doi.org/10.1016/j.vetmic.2008.02.027>

Buller, B.N., 2014. *Bacteria and Fungi from Fish and other Aquatic Animals*. CABI Publishing.

Chu, C., Huang, P.Y., Chen, H.M., Wang, Y.H., Tsai, I.A., Lu, C.C., Chen, C.C., 2016. Genetic and pathogenic difference between *Streptococcus agalactiae* serotype Ia fish and human isolates. *BMC Microbiol.* 16, 16-175. <https://doi.org/10.1186/s12866-016-0794-4>

[CLSI] Clinical and Laboratory Standards Institute, 2020. Performance standards for antimicrobial susceptibility testing for bacteria isolated from aquatic animals. In: *CLSI Supplement VET04, third ed.* Clinical and Laboratory Standards Institute, Wayne, PA.

Cowan, S.T., Steel, K.J., 1993. *Cowan and Steel's Manual for Identification of Medical Bacteria*, third ed. University Press, Cambridge.

Deng, M., Yu, Z., Geng, Y., Wang, K., Chen, D., Huang, X., Ou, Y., Chen, Z., Zhong, Z., Lai, W., 2017. Outbreaks of Streptococcosis associated with *Streptococcus iniae* in Siberian sturgeon (*Acipenser baerii*) in China. *Aqua Res.* 48, 909-919. <https://doi.org/10.1111/are.12934>

Deng, L., Li, Y., Geng, Y., Zheng, L., Rehman, T., Zhao, R., Lai, W., 2019. Molecular serotyping and antimicrobial susceptibility of *Streptococcus agalactiae* isolated from fish in China. *Aquaculture*. 510, 84-89. <https://doi.org/10.1016/j.aquaculture.2019.05.046>

Dinh-Hung, N., Dong, H. T., Soontara, C., Rodkhum, C., Nimitkul, S., Srisapoome, P., Chatchaiphan, S., 2022. Co-infection of *Candidatus piscichlamydia trichopodus* (Order Chlamydiales) and *Henneguya* sp. (Myxosporae, Myxobolidae) in Snakeskin Gourami *Trichopodus pectoralis* (Regan 1910). *Front. Vet. Sci.* 9, 847977. <https://doi.org/10.3389/fvets.2022.847977>

Dinh-Hung, N., Dong, H.T., Shinn, A.P., Rodkhum, C., Phiwsaiya, K., Wichianrat, C., Chatchaiphan, S., 2023a. Lumpy skin disease of snakeskin gourami: a new record of metacercariae of *Posthodiplostomum* sp. (Digenea, Diplostomidae) in clinically sick snakeskin gourami, *Trichopodus pectoralis* Regan, 1910 (Pisces, Osphronemidae). *Aquaculture*. 573, 739583.

- Dinh-Hung, N., Dong, H.T., Taengphu, S., Soontara, C., Rodkhum, C., Senapin, S., Chatchaiphan S., 2023b. *Streptococcus suis* is a lethal pathogen in snakeskin gourami, *Trichopodus pectoralis*. *Aquaculture*. 566, 739173. <https://doi.org/10.1016/j.aquaculture.2022.739173>
- Dung, T.T., Khoi, L.M., Trung, N.B., 2019. Isolation, identification and characterization of *Aeromonas schubertii* causing internal white spots on snakehead fish (*Channa striata*) in the Mekong Delta of Vietnam. *Can Tho University Journal of Science*. 55, 69–78.
- Dung, T.T., Khoi, L.M., Trung, N.B., 2019. Isolation, identification and characterization of *Aeromonas schubertii* causing internal white spot on snakehead fish (*Channa striata*) in the Mekong Delta of Vietnam. *Can Tho University Journal of Science*. 55, 69–78.
- Duremdez, R., Al-Marzouk, A., Qasem, J.A., Al-Harbi, A., Gharabally, H., 2004. Isolation of *Streptococcus agalactiae* from cultured silver pomfret, *Pampus argenteus* (Euphrasen), in Kuwait. *J. Fish Dis.* 27, 307–310. <https://doi.org/10.1111/j.1365-2761.2004.00538.x>
- Eldar, A., Bejerano, Y., Bercovier, H., 1994. *Streptococcus shiloi* and *Streptococcus difficile*: two new streptococcal species causing a meningo-encephalitis in fish. *Curr. Microbiol.* 28, 139–143.
- El-Noby, G., Hassanin, M., El-Hady, M., Aboshabana, S., 2021. Streptococcus: a review article on an emerging pathogen of farmed fishes. *Egyptian Journal of Aquatic Biology and Fisheries*. 2, 123–139.
- Frerichs, G.N., Millar, S.D., 1993. *Manual for the isolate and identification of fish bacterial pathogens*. Pisces Press, Scotland.
- Fry, J.P., Cabello, F., Good, C.M., Lunestad, B.T., 2020. Veterinary drug use in United States net pen Salmon aquaculture: implications for drug use policy. *Love. Aquaculture*. 518, 734820. <https://doi.org/10.1016/j.aquaculture.2019.734820>
- Gustiano, R., Iskandariah, I., Ath-Thar, M.F., Huwoyon, G.H., Radona, D., 2022. Domestication of snakeskin gourami (*Trichopodus pectoralis* Regan, 1910) in Indonesia: characterization, bioreproduction and early development. *Pakistan J. Zool.* 56, 185–192. <https://doi.org/10.17582/journal.pjz/20220111140146>
- Heuer, H., Krsek, M., Baker, P., Smalla, K., Wellington, E.M., 1997. Analysis of actinomycete communities by specific amplification of genes encoding 16S rRNA and gel-electrophoretic separation in denaturing gradients. *Appl. Environ. Microbiol.* 63, 3233–3241. <https://doi.org/10.1128/aem.63.8.3233-3241.1997>
- Hoa, T.T.T., Boerlage, A.S., Duyen T.T.M., Thy, D.T.M., Hang, N.T.T., Humphry, R.W., Phuong, N.T., 2021. Nursing stages of striped catfish (*Pangasianodon hypophthalmus*) in Vietnam: pathogens, diseases and husbandry practices. *Aquaculture*. 533, 736114. <https://doi.org/10.1016/j.aquaculture.2020.736114>
- Hoai, T.D., Ninh D.T., Trinh, T.T., Hoa, D.T., Tuan, N.N., Van, K.V., 2022. Isolation and antibiotic susceptibility of *Flavobacterium columnare* infecting grass carp cultured in Northern Vietnam. *Vietnam J. Agri.* 20, 732–740.
- Huong, L.Q., Nguyen, T.B.T., Nguyen, T.L.A., Do, T.T.T., Dao, T.H.T., Padungtod, P., 2021. Antibiotics use in fish and shrimp farms in Vietnam. *Aquac. Rep.* 20, 100711. <https://doi.org/10.1016/j.aqrep.2021.100711>
- Inglis, V., Roberts, R.J., Bromage, N.R., 1993. *Bacterial disease of fish*. The University Press Cambridge, Cambridge.
- Irshath, A.A., Rajan, A., Vimal, S., Prabhakaran, V.S., Ganesan, R., 2023. Bacterial pathogenesis in various fish diseases: recent advances and specific challenges in vaccine development. *Vaccines*, 11, 470. <https://doi.org/10.3390/vaccines11020470>
- Jimenez, A.P., Tibatá, V.M., Junca, H., Ariza, F., Verjan, N., Iregui, C.A., 2011. Evaluating a nested-PCR assay for detecting *Streptococcus agalactiae* in red tilapia (*Oreochromis* sp.) tissue. *Aquaculture*. 321, 203–206. <https://doi.org/10.1016/j.aquaculture.2011.09.011>
- Kayansamruaj, P., Pirarat, N., Katagiri, T., Hirono, I., Rodkhum, C., 2014. Molecular characterization and virulence gene profiling of pathogenic *Streptococcus agalactiae* populations from tilapia (*Oreochromis* sp.) farms in Thailand. *J. Vet. Diagn. Invest.* 26, 488–495.
- Khoang, T.L., Nguyen, N.C., Phu, T.Q., Oanh, D.T.H., 2020. Effect of temperatures on the susceptibility of whiteleg shrimp (*Litopenaeus vannamei*) to *Vibrio parahaemolyticus*. *Can Tho University Journal of Science*. 56, 38–44.
- Klingklib, C. Suanyuk, N., 2017. *Streptococcus agalactiae* serotype Ib, an emerging pathogen affecting climbing perch (*Anabas testudineus*) and Günther's walking catfish (*Clarias macrocephalus*) polycultured in southern Thailand. *The Thai Journal of Veterinary Medicine*. 47, 5. <https://he01.tci-thaijo.org/index.php/tjvm/article/view/90276>
- Leal, C.A.G., Queiroz, G.A., Pereira, FL., Tavares, G.C., Figueiredo, H.C.P., 2019. *Streptococcus agalactiae* sequence type 283 in farmed fish, Brazil. *Emerging Infect. Dis.* 25, 776–779. <https://doi.org/10.3201/eid2504.180543>
- Liu, L., Li, Y. W., He, R.Z., Xiao, X.X., Zhang, X., Su, Y.L., Wang, J., Li, A.X., 2014. Outbreak of *Streptococcus agalactiae* infection in barcoo grunter, *Scortum barcoo* (McCulloch & Waite), in an intensive fish farm in China. *J. Fish Dis.* 37, 1067–72. <https://doi.org/10.1111/jfd.12187>
- Long, D.N., Tuan, N.A., Lan, L.M., 2014 *Textbook on Freshwater Farming Techniques*. Can Tho University Publishers.
- Mai, L.T.P., Son, V.N., Huong, D.T.T., Ni, D.V., Hai, T.N., 2016. Evaluation of the effect of salinity on zebrafish (*Trichogaster pectoralis*) and fish farming ability in Hau Giang province under saline intrusion due to climate change. *Can Tho University Journal of Science*. 43, 133–142.
- Minh, N.P., Mai, P.X., Linh, N.T., 2019. Physical aspects influencing to the production of dry-salted snakeskin gourami (*Trichogaster pectoralis*). *Orient. J. Chem.* 35, 773–777. <https://doi.org/10.13005/ojc/350238>
- Miranda, C.D., Godoy, F.A., Lee, M.R., 2018. Current status of the use of antibiotics and the antimicrobial resistance in the Chilean salmon farms. *Front. Microbiol.* 9, 1284. <https://doi.org/10.3389/fmicb.2018.01284>
- Mishra, A., Nam, G.H., Gim, J.A., Lee, H.E., Jo, A., Kim, H.S., 2018. Current challenges of *Streptococcus* infection and effective molecular, cellular, and environmental control methods in aquaculture. *Mol. Cells*. 41, 495–505. <https://doi.org/10.14348/molcells.2018.2154>
- Moore, E., Arnscheidt, A., Kruger, A., Strompl, C., Mau, M., 2004. Simplified protocols for the preparation of genomic DNA from bacterial cultures. *Molecular Microbial Ecology Manual, Second Edition*. 101, 3–18.
- Muoi, N.V., Truc, T.T., 2008. Effect of different solutes on water activity of dried Snakeskin fish (*Trichogaster pectoralis* Regan). *Can Tho University Journal of Science*. 10, 151–160.
- Ndashe, K., Hang'ombe, B. M., Changula, K., Yabe, J., Samutela, M.T., Songe, M.M., Kefi, A.S., Njobvu, C.L., Sukkel, M., 2023. An assessment of the risk factors associated with disease outbreaks across Tilapia farms in central and Southern Zambia. *Fishes*. 8, 49. <https://doi.org/10.3390/fishes8010049>
- Netto, L.N., Leal, C.A., Figueiredo, H.C., 2011. *Streptococcus dysgalactiae* as an agent of septicemia in Nile tilapia, *Oreochromis niloticus* (L.). *J. Fish Dis.* 34, 251–254. <https://doi.org/10.1111/j.1365-2761.2010.01220.x>
- Nho, S.W., Hikima, J., Park, S.B., Jang, H.B., Cha, I.S., Yasuike, M., Nakamura, Y., Fujiwara, A., Sano, M., Kanai, K., 2013. Comparative genomic characterization of three *Streptococcus parauberis* strains in fish pathogen, as assessed by wide-genome analyses. *PLoS One*. 8, e80395. <https://doi.org/10.1371/journal.pone.0080395>

- Niu, G., Khattiya, R., Zhang, T., Boonyayatra, S., Wongsathein, D., 2020. Phenotypic, genotypic characterization of *Streptococcus* spp. isolated from tilapia (*Oreochromis* spp.) cultured in river-based cage and earthen ponds in Northern Thailand. *J. Fish Dis.* 43, 391-398. <https://doi.org/10.1111/jfd.13137>
- Oanh, D.T.H., Phuong, N.T., 2012. Isolation and characterization of *Streptococcus agalactiae* from red tilapia (*Oreochromis* sp.) eye edema and hemorrhage. *Can Tho University Journal of Science.* 22, 206-207.
- Oanh, D.T.H., Phuong, N.T., 2012. Isolation and characterization of *Streptococcus agalactiae* from red tilapia (*Oreochromis* sp.) eye edema and hemorrhage. *Can Tho University Journal of Science.* 22, 206-207.
- Ortega, A.Y., Barreiro, S.F., Bueno, M.H., Huancaré, P.K., Ostos, A.H., Manchego, S.A., Pereira, F.M.A., Gómez, M.W., Andrade, B.M. A., Sandoval, C.N., 2016. First report of *Streptococcus agalactiae* isolated from *Oreochromis niloticus* in Piura, Peru: molecular identification and histopathological lesions. *Aquaculture Reports.* 4, 74-79. <https://doi.org/10.1016/j.aqrep.2016.06.002>
- Pepi, M., Focardi S., 2021. Antibiotic-resistant bacteria in aquaculture and climate change: a challenge for health in the mediterranean area. *Int. J. Environ. Res. Public Health.* 8, 5723. <https://doi.org/10.3390/ijerph18115723>
- Phong, N.T.D., 2014. Snakeskin gourami in the Mekong. *Aqua Cult. Asia Pac.* 10, 23-27.
- Phuoc, N.N., Anh, T.T.N., Linh, N.T.H.L., 2019. Isolation and bio-chemical characteristics of *Streptococcus agalactiae* from diseased red tilapia in Thua Thien Hue province. *Journal of Science-Hue University.* 3, 1591-1601
- Pradeep, P.J., Suebsing, R., Sirthammajak, S., Kampeera, J., Jitrakorn, S., Saksmerprome, V., Turner, W., Pulido, E., Iregui, C., 2016. Hibridación in situ para la detección de *Streptococcus agalactiae* en tejidos de tilapia (*Oreochromis* sp.). *Rev. Fac. Med. Vet. Zoot.* 57, 11-22.
- Pulkkinen, K., Suomalainen, L.R., Read, A.F., 2010. Intensive fish farming and the evolution of pathogen virulence: the case of columnaris disease in Finland. *Proc Biol Sci.* 277, 593-600. <https://doi.org/10.1098/rspb.2009.1659>
- Pulpipat, T., Boonyawiwat, V., Moonjit, P., Sanguankiat, A., Phatthanakunanan, S., Jala, S., Surachetpong, W., 2023. *Streptococcus agalactiae* Serotype VII, an emerging pathogen affecting snakeskin gourami (*Trichogaster pectoralis*) in Intensive farming. *Transbound. Emerg. Dis.* 2023, 13. <https://doi.org/10.1155/2023/1682047>
- Reed, L.J., Muench, H., 1938. A simple method of estimating fifty percent and points. *Am. J. Hyg.* 27, 493-497. <https://doi.org/10.1093/oxfordjournals.aje.a118408>
- Reyes, A.T., Fajardo, L.J., Abando, A.K.Y., 2019. Antibiotic susceptibility of *Streptococcus agalactiae* isolated from Tilapia pond sediment in Lubao, Pampanga, Philippines. *J. Drug Deliv. Ther.* 9, 370-375. <https://doi.org/10.22270/jddt.v9i2-s.2530>
- Saitou, N., Nei, M., 1987. The neighbor-joining method: a new method for reconstructing phylogenetic trees. *Mol. Biol. Evol.* 4, 406-425. <https://doi.org/10.1093/oxfordjournals.molbev.a040454>
- Sapugahawatte, D.N., Li, C., Dharmaratne, P., Zhu, C., Yeoh, Y.K., Yang, J., Lo, N.W.S., Wong, K.T., Ip M., 2022. Prevalence and characteristics of *Streptococcus agalactiae* from freshwater fish and pork in Hong Kong wet markets. *Antibiotics.* 11, 397. <https://doi.org/10.3390/antibiotics11030397>
- Serwecińska, L., 2020. Antimicrobials and antibiotic-resistant bacteria: a risk to the environment and to public health. *Water.* 12, 3313. <https://doi.org/10.3390/w12123313>
- Sheehan, B., 2009. Streptococcosis in tilapia: a more complex problem than expected, in: Behrend, H., (Eds.), *Managing Streptococcus in Warmwater Fish 25 September 2009.* Intervet Schering-Plough Animal Health, Veracruz, pp, 9-14.
- Sundberg, L.R., Ketola, T., Laanto, E., Kinnula, H., Bamford, J.K.H., Penttinen, R., Mappes, J., 2016. Intensive aquaculture selects for increased virulence and interference competition in bacteria. *Proc. R. Soc.* 283, 20153069. <https://doi.org/10.1098/rspb.2015.3069>
- Tacon, A.G., Hasan, M.R., Metian, M., Demand, 2011. *Demand and supply of Feed Ingredients for Farmed Fish and Crustaceans: Trends and Prospects.* FAO, Rome.
- Tamura, K., Stecher, G., Peterson, D., Filipinski, A., Kumar, S., 2013. MEGA6: Molecular evolutionary genetics analysis version 6.0. *Mol. Biol. Evol.* 30, 2725-2729. <https://doi.org/10.1093/molbev/mst197>
- Truc, T.T., Doan, D.T.K., Muoi, N.V., 2009. Effect of sorbitol and ethanol on the aw and quality changes of dried snakeskin fish. *Can Tho University Journal of Science.* 11, 317-326.
- Van Doan, H., Soltani, M., Leitao, A., Shafiei, S., Asadi, S., Lymbery, A.J., Ringø, E., 2022. Streptococcosis a re-emerging disease in aquaculture: significance and phytotherapy. *Animals.* 12, 2443. <https://doi.org/10.3390/ani12182443>
- Wang, K., Chen, D., Huang, L., Lian, H., Wang, J., Xiao, D., Lai, W.M., 2013. Isolation and characterization of *Streptococcus agalactiae* from Nile Tilapia *Oreochromis niloticus* in China. *Afr. J. Microbiol. Res.* 7, 317-323. <https://doi.org/10.5897/AJMR12.1207>
- Wongsathein, D., Kaewngernsong, N., Raksri, S., Khattiya, R., Potha, T., Boonyayatra, S., 2018. Identification and characterization of *Streptococcus agalactiae* recovered from farmed tilapia in Chiang Mai. *Vet. Integr. Sci.* 16, 271-284.
- Wongsathein, D., 2012. Factors Affecting Experimental *Streptococcus agalactiae* Infection in Tilapia, *Oreochromis niloticus* [Dissertation]. Stirling, UK: University of Stirling.
- Wongsathein, D., Raksri, S., Urit, T., Kaewngernsong N., 2019. Experimental *Streptococcus agalactiae* infection in Nile tilapia (*Oreochromis niloticus*) via different routes. *Vet. Integr. Sci.* 17, 233-243.
- Yang, W., Li, A., 2009. Isolation and characterization of *Streptococcus dysgalactiae* from diseased *Acipenser schrenckii*. *Aquaculture.* 294, 14-17. <https://doi.org/10.1016/j.aquaculture.2009.05.018>
- Yanong, P.E.R., Francis-Floyd, R., 2002. Streptococcal infections of fish. *Institute of Food and Agricultural Sciences. University of Florida.* 1, 5.
- Yuan, X.Lv.Z., Zhang, Z., Han, Y., Liu, Z., Zhang, H., 2023. A review of antibiotics, antibiotic resistant bacteria, and resistance genes in aquaculture: occurrence, contamination, and transmission. *Toxics.* 11, 420. <https://doi.org/10.3390/toxics11050420>
- Ziarati, M., Zorriehzabra, M.J., Hassantabar, F., Mehrabi, Z., Dhawan, M., Sharun, K., Emran, T.B., Dhama, K., Chaicumpa, W., Shamsi, S., 2022. Zoonotic diseases of fish and their prevention and control. *Vet Q.* 42, 95-118. <https://doi.org/10.1080/01652176.2022.2080298>