

## Diagnosis and treatment of *Anaplasma centrale* in a domestic cat at Animal Hospital of Hasanuddin University Makassar

Vannesa Valensie, Wa Ode Santa Monica\*, Dian Fatmawati, Aniza Putri Sissiri

Program of Veterinary Professional, Faculty of Medicine, Hasanuddin University, Makassar

**ABSTRACT:** Anaplasmosis is a disease caused by obligate gram-negative intracellular bacteria. *Anaplasma* in cats is generally infected by *Anaplasma phagocytophilum*, however there are very limited reports of *Anaplasma bovis* such as *Anaplasma marginale* and *Anaplasma centrale* being reported to infect cats. This is the first report of anaplasmosis caused by *Anaplasma centrale* in cats. The owner brought a one-year-old female domestic cat to the Animal Hospital of Hasanuddin University in Makassar with the condition of not wanting to eat, weak, lethargic, dehydrated, and not defaecating. Diagnosis is carried out through anamnesis, physical examination, clinical examination, and laboratory examination, in the form of haematology and blood smear tests. The results of the examination revealed flea infestation, a blood test identified *Anaplasma centrale* with characteristics such as the presence of morulae in the middle part of the erythrocytes, and routine blood work showed anaemia which was seen in the MCV parameters increasing and the MCHC values decreased. Treatment consists of administration of antibiotics, anti-inflammatory drugs, and supportive therapy. The cat showed good results, with symptoms starting to disappear and the animal appeared active.

### Keywords:

Anaplasmosis, *Anaplasma bovis*, *Anaplasma centrale*, domestic cat

### ■ INTRODUCTION

Anaplasmosis is a disease caused by one of two gram-negative obligate intracellular bacterial agents, *Anaplasma phagocytophilum*, with the characteristic presence of intracytoplasmic morulae in white blood cells. The main vector of *Anaplasma phagocytophilum* is ticks from the genus *Ixodes*, namely the *Ixodes ricinus* and *Ixodes persulcatus* complex (Sykes 2013). Detection of anaplasmosis in animals can generally be performed through blood smear tests until PCR (Gorna *et al.* 2013). Clinical signs visible during physical examination in cats include fever, lethargy, tachypnoea, ataxia, hyperesthesia, muscle and joint pain, lameness, conjunctivitis, and ocular discharge (Sykes 2013). The condition of fleas and long hair on an animal's body can increase the degree of tick infestation because damp conditions provide a favourable environment for ticks (Arsyitahlia *et al.* 2021).

Anaplasmosis in cats is generally caused by *Anaplasma phagocytophilum*, however there are very limited reports of *Anaplasma bovis* such as *Anaplasma marginale* and *Anaplasma centrale* being reported to infect cats. There are only a few reports on the occurrence of *Anaplasma centrale* in Felidae wildlife in Africa (Makgabo *et al.* 2023), and this was also reported in a limited number of samples (Oliveira *et al.* 2018, André 2018). Reports of anaplasmosis in cats in Indonesia are also difficult to find, and there are only reports in dogs (Wardani *et al.* 2023). This study is the first to report the incidence of *Anaplasma centrale* in cats and the treatment carried out at the Animal Hospital of Hassanudin University, Makassar.

### ■ CASE

**Signalement:** Domestic cat, female, 1 year old, weight 3.9 kg. The cat did not want to eat, was weak, lethargic, dehydrated, and had not defaecated a day before (Figure 1A).

**Anamnesis:** The cat has been kept since the age of 3 months. The cats were kept in-house. Deworming medications and vaccines were administered. **Physical Examination:** The results of the physical examination are shown in Table 1.

**Haematology:** The cat had anaemia, characterised by a decrease in MCHC because the body had lost a lot of blood cells. MCV increases because of the larger size of the red blood cells. **Blood Smear:** A blood smear found a round dot in the middle of the erythrocyte cell (Figure 1B).

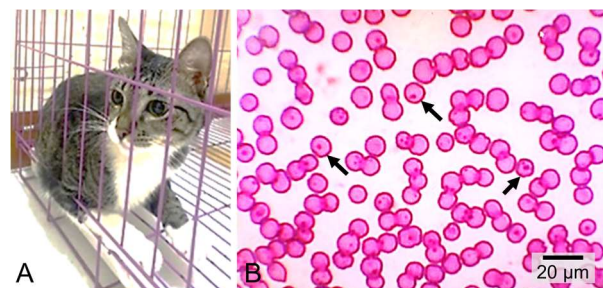


Figure 1. Cat conditions and blood smear test results. (A) The condition of a cat infected with *Anaplasma centrale* and (B) intracytoplasmic inclusions (arrow) at the centre of the erythrocyte body as *Anaplasma centrale* at 1000x magnification with Giemsa staining.

Received: 06-09-2023 | Revised: 12-10-2023 | Accepted: 15-10-2023

© 2023 CC-BY-SA. This is an Open Access article distributed under the terms of the Creative Commons Attribution ShareAlike 4.0 International License (<https://creativecommons.org/licenses/by-sa/4.0/>).

Table 1. Physical examination of a cat infected with anaplasmosis.

No	Physical Examination	Results	Normal	Note
1.	Heart beat (x/min)	128	90 - 120	Increase
2.	Pulsus (x/min)	128	90 - 120	Increase
3.	Capillary Refill Test (s)	> 2	< 2	Dehydration
4.	Respiration (x/min)	44	20 - 40	Increase
5.	Rectal temperature (°C)	38.8	37.7 - 38.8	Normal

**Diagnosis:** Anaplasmosis. **Prognosis:** Fausta. **Therapy:** Causative, symptomatic, and supportive therapy. Causative therapy was administered doxycycline (5 mg/kg BW, for 14 days) PO. Symptomatic therapy was administered by Meloxicam® (0.2 mg/kg for 5 days) PO and Sangobion® PO for 7 days. Supportive therapy was given by Ringer Lactate® infusion {fluid requirements for maintenance = (30 × kg BW) + 70} and Neurosanbe® 1 ml IV, Curcuma® + Imboost® + Gold-G® (6:3:1) 1 ml PO.

## ■ RESULTS AND DISCUSSION

The results of blood tests are shown in Table 2. Haematology revealed anaemia in the form of increased cell volume (MCV) and decreased average haemoglobin levels (MCHC). A high MCV value indicates that the red blood cell volume is above normal or too large (macrocytosis) by the infecting *Anaplasma*. The MCHC value was low because erythrocytes were lysed.

Animals infected with anaplasmosis experience anaemia owing to ticks that suck the host's blood (Arsyitahlia *et al.* 2021). In addition, anaemia can also be caused by the lysis of red blood cells due to anaplasmosis infection in host cells. Parasites infecting host red blood cells cause acute haemolysis during the developmental stages of the agent (Underwood *et al.* 2015). Blood smear examination of the cat revealed intracytoplasmic inclusions (morula). Intracytoplasmic morules in red blood cells in the body centre indicate that a cat is infected with *Anaplasma centrale* (André 2018).

Table 2. Haematological profile of a cat infected with anaplasmosis.

Item	Result	Unit	Alarm	References <sup>(*)</sup>
WBC	14.2	10 <sup>9</sup> /L		5.5 - 19.5
Lymph#	3.3	10 <sup>9</sup> /L		0.8 - 7.0
Mid#	2.4	10 <sup>9</sup> /L	↑	0.0 - 1.9
Gran#	8.5	10 <sup>9</sup> /L		2.1 - 15.0
Lymph%	23.1	%		12.0 - 45.0
Mid%	16.9	%	↑	2.0 - 9.0
Gran%	60.0	%		35.0 - 85.0
RBC	7.33	10 <sup>12</sup> /L		4.60 - 10.00
HGB	11.2	g/dL		9.3 - 15.3
HCT	39.4	%		28.0 - 49.0
MCV	53.8	fL	↑	39.0 - 52.0
MCH	15.2	pg		13.0 - 21.0
MCHC	284	g/L	↓	300 - 380
PLT	109	10 <sup>9</sup> /L		100 - 514
MPV	10.0	fL		5.0 - 11.8
PDW	9.9			5.0 - 20.0
PCT	0.109	%		0.100 - 0.500
P-LCC	74	10 <sup>9</sup> /L		
P-LCR	68.8	%		10.0 - 70.0

Note: sources Putra *et al.* 2019, WBC=white blood cells, Lymph=lymphocyte, Mid=agranulocyte, Gran=granulocyte, RBC=red blood cells, HGB=hemoglobin, HCT=hematocrit, MCV=mean corpuscular volume, MCH=mean corpuscular hemoglobin, MCHC=mean corpuscular hemoglobin concentration, PLT=platelet, MPV=mean platelet volume, PDW=platelet distribution width, PCT=procalcitonin, P-LCC=platelet-large cell concentration, P-LCR=platelet-large cell ratio.

The antibiotic doxycycline was used because it is capable of intracellular penetration and is bacteriostatic (Yancey *et al.* 2018). Meloxicam® inhibits the formation of inflammatory mediator prostaglandins (Priyanka *et al.* 2017). Sangobion® supports iron as an important mineral for the production of RBCs. Ringer Lactat® infusion combined with Neurosanbe® to restore body fluids and help the formation of red blood cells and nerves. Curcuma®, Gold-G®, and Imboost® have been used to increase immunity (Putra *et al.* 2019). Treatment showed good results, and on the third day, the symptoms began to disappear, the animal looked active, and was given outpatient care.

## ■ CONCLUSION

Cats were infected with *Anaplasma centrale* based on blood smear findings showing intracytoplasmic inclusions in the middle of the erythrocyte bodies.

## ■ AUTHOR INFORMATION

### Author for Correspondence

\*WOSM: santawaode@med.unhas.ac.id

Program of Veterinary Professional, Faculty of Medicine, Hasanudin University, Jln. Perintis Kemerdekaan KM. 10 Makassar.

## ■ REFERENCES

- André MR. 2018. Diversity of *Anaplasma* and *Ehrlichia/Neoehrlichia* agents in terrestrial wild carnivores worldwide: implications for human and domestic animal health and wildlife conservation. *Frontiers in veterinary science*. 5(2018):293-317.
- Arsyitahlia N, Suartha IN, Soma IG. 2021. Laporan kasus: anaplasmosis pada anjing peranakan Kintamani. *Indonesia Medicus Veterinus*. 10(2):304-315.
- Gorna M, Adaszek L, Policht K, Skrzypczak M, Winiarczyk S. 2013. Detection of *Anaplasma phagocytophilum* in a cat. *Veterinárni medicína*. 58(1):39-43.
- Makgabo SM, Brayton KA, Oosthuizen MC, Collins NE. 2023. Unravelling the diversity of *Anaplasma* species circulating in selected African wildlife hosts by targeted 16S microbiome analysis. *Current Research in Microbial Sciences*. 5(2023):100198.
- Oliveira AC, Luz MF, Granada S, Vilhena H, Nachum-Biala Y, Lopes AP, Cardoso L, Baneth G. 2018. Molecular detection of *Anaplasma bovis*, *Ehrlichia canis* and *Hepatozoon felis* in cats from Luanda, Angola. *Parasites & vectors*. 11(1):1-6.
- Priyanka M, Dhanalakshmi H, Rakesh RL, Thimmareddy PM, Narayana Bhat M. 2017. Monocytic anaplasmosis in a cow: a case report. *Journal of Parasitic Diseases*. 41(2017):687-688.
- Putra WG, Widyastuti SK, Batan IW. 2019. Laporan kasus: anaplasmosis dan ehrlichiosis pada anjing kampung di Denpasar, Bali. *Indonesia Medicus Veterinus*. 8(4):502-512.
- Sykes JE. 2013. *Canine and Feline Infectious Diseases*. Missouri: Elsevier.
- Underwood WJ, Blauwiel R, Delano ML, Gillesby R, Mischler SA, Schoell A. 2015. *Biology and Diseases of Ruminants (Sheep, Goats, and Cattle)*, in: *Laboratory Animal Medicine*. Elsevier, pp. 623-694.
- Wardani PI, Putriningsih PA, Soma IG. 2023. Dermatitis due to *Sarcoptes scabiei* and *Rhipicephalus sanguineus* accompanied by anaplasmosis in Shih-tzu mixed dog. *Veterinary Science and Medicine Journal*. 5(10):290-302.
- Yancey CB, Diniz PP, Breitschwerdt EB, Hegarty BC, Wiesen C, Qurollo BA. 2018. Doxycycline treatment efficacy in dogs with naturally occurring *Anaplasma phagocytophilum* infection. *Journal of Small Animal Practice*. 59(5):286-293.